JSB
Journée Scientifique de Broca

L’ échographie thoracique pour le gériatre

Quoi de neuf ?

A. HACIL (Paris)



Pas de conflit d'intéret

Annie 91 ans Dyspnée

Vit en EHPAD

ATCD : Cardiopathie ischémique, HTA, chute, TNC mixte
TRT : Bisoprolol, Losartan, Kardégic, Lasilix, Tahor.

Clinique : Sat 98% en AA, quelques crépitants bilatéraux asymétrique, discret OMI.

Bio: GB 12000 G/L, **CRP** 36 mg/l, **créatinine** 112 µmol/l
Hb 10,2 g/dl, **Protéine** 67 g/l,**Troponine** 45 ng /l,
Nt proBNP 4200 ng/l.
PCR Covid positive.



Annie 91 ans Dyspnée

Quels diagnostics retenir ?

A- Insuffisance cardiaque décompensée

B- Pneumopathie

C- Epanchement pleural

D- Infection virale (Covid)



Annie 91 ans Dyspnée

Quel examen demandé ?

A- Radiographie thoracique

B- Scanner thoracique

C- Echographie cardiaque

D- Echographie thoracique

E- ECG



L'échographie thoracique ?

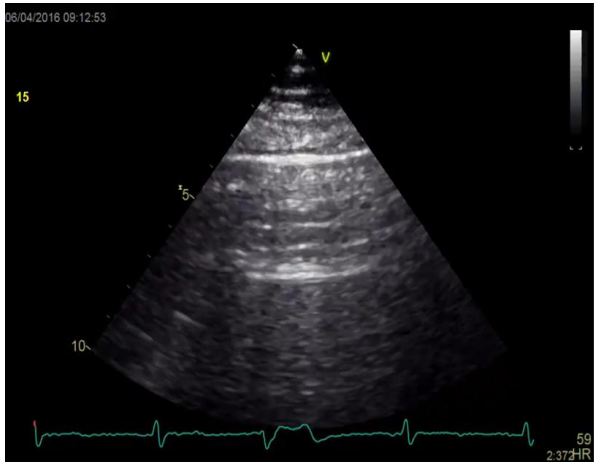



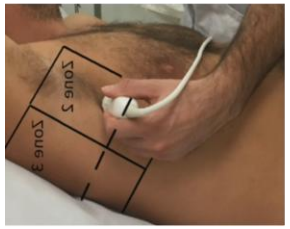



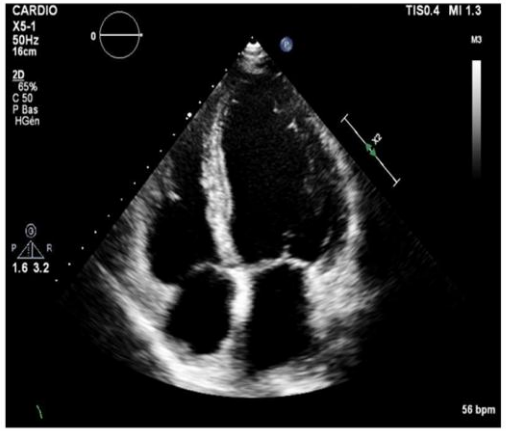

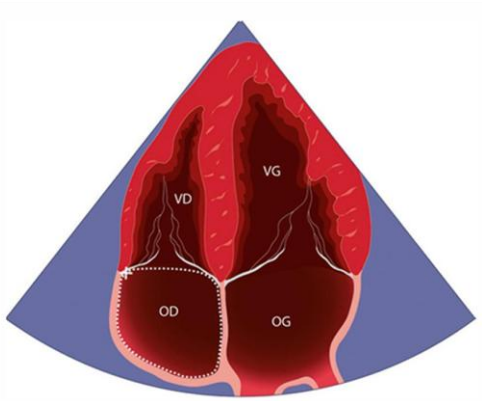





L'échographie pulmonaire

Glissement pleural

Ligne A

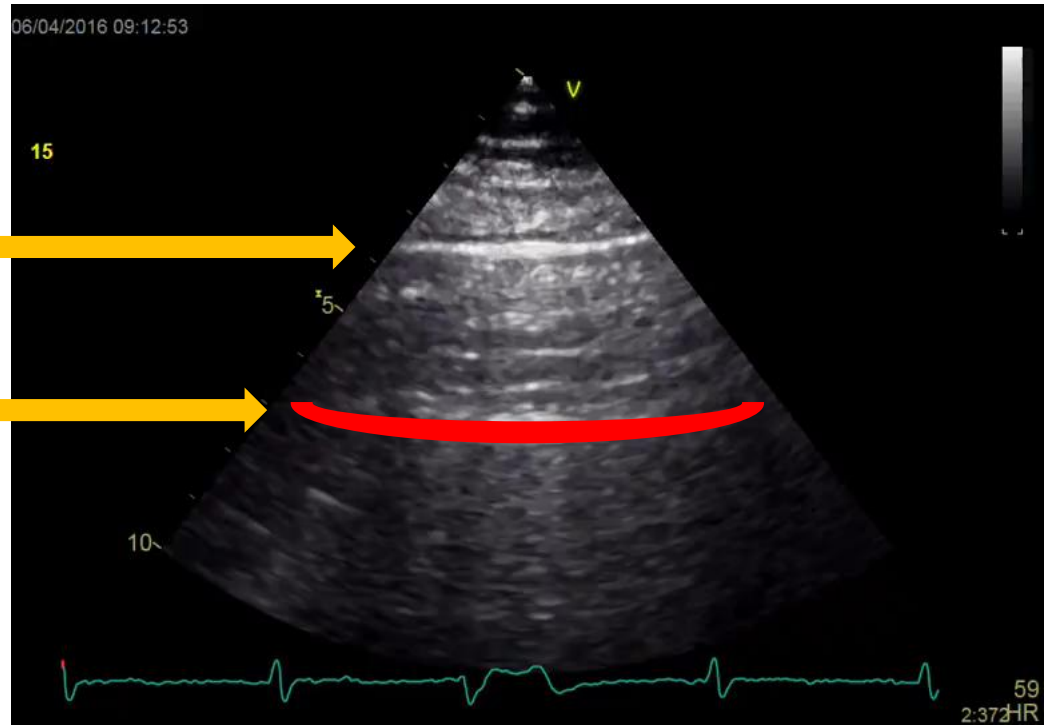



Lignes A

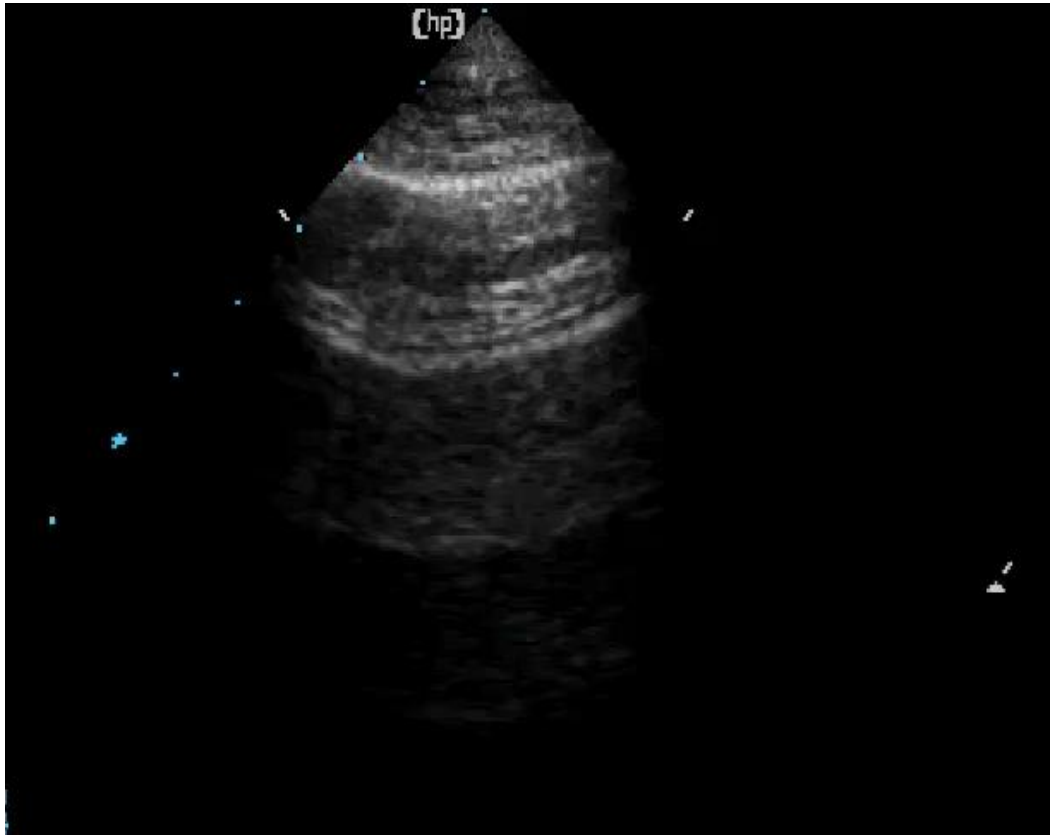

Lignes B



Principe simple !

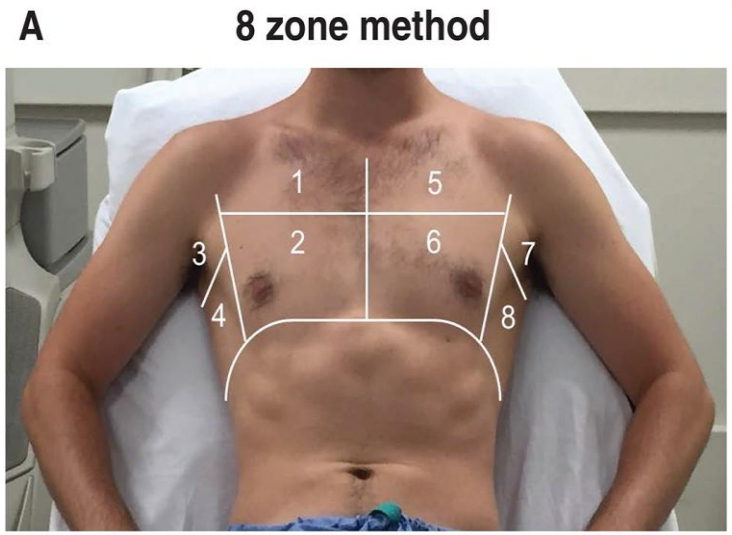













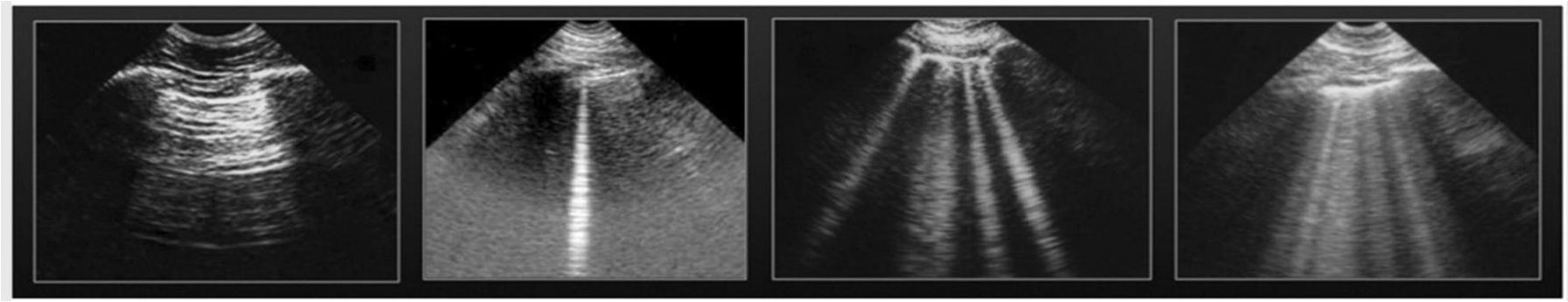

Diagnostic échographique de la décompensation cardiaque

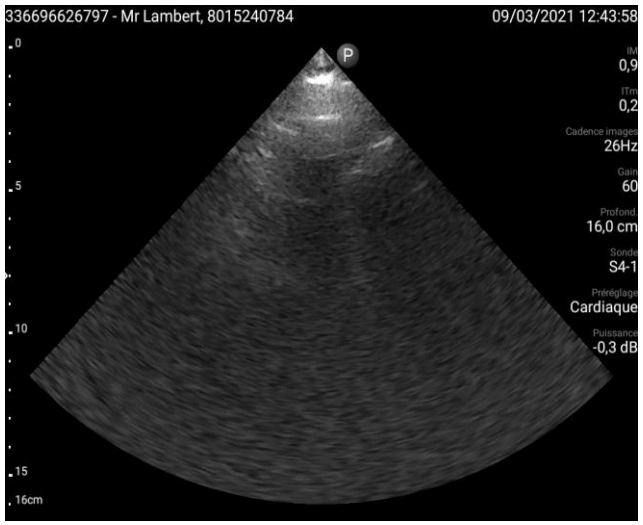



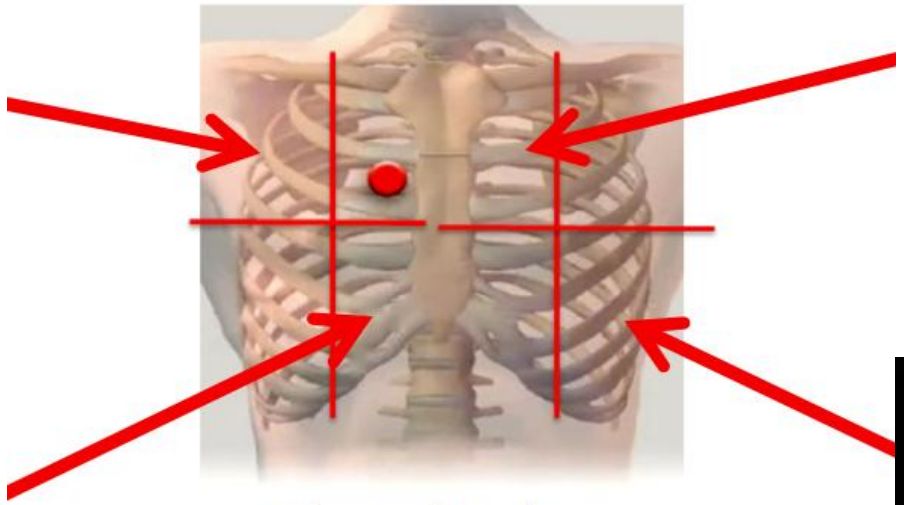

>3 comètes / zone,
2 zones + bilaterales
= IC aigue!

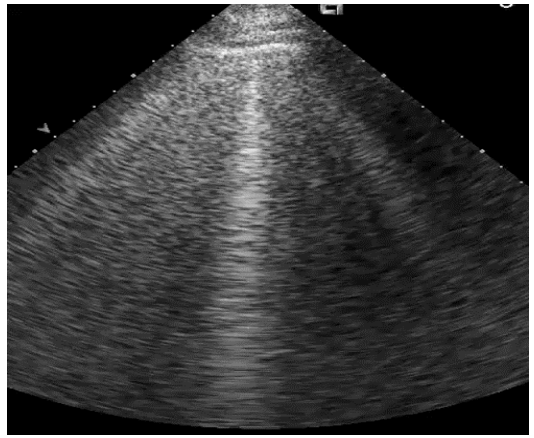

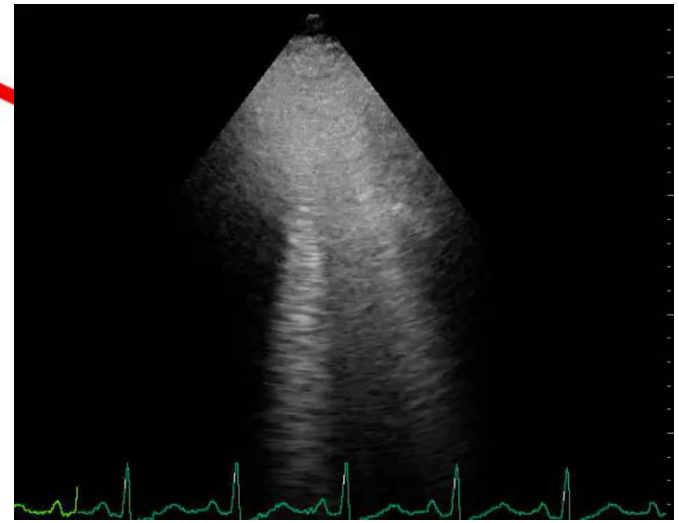

ESC 2026 : l'échographie pulmonaire dans le diagnostic de l'IC décompensée

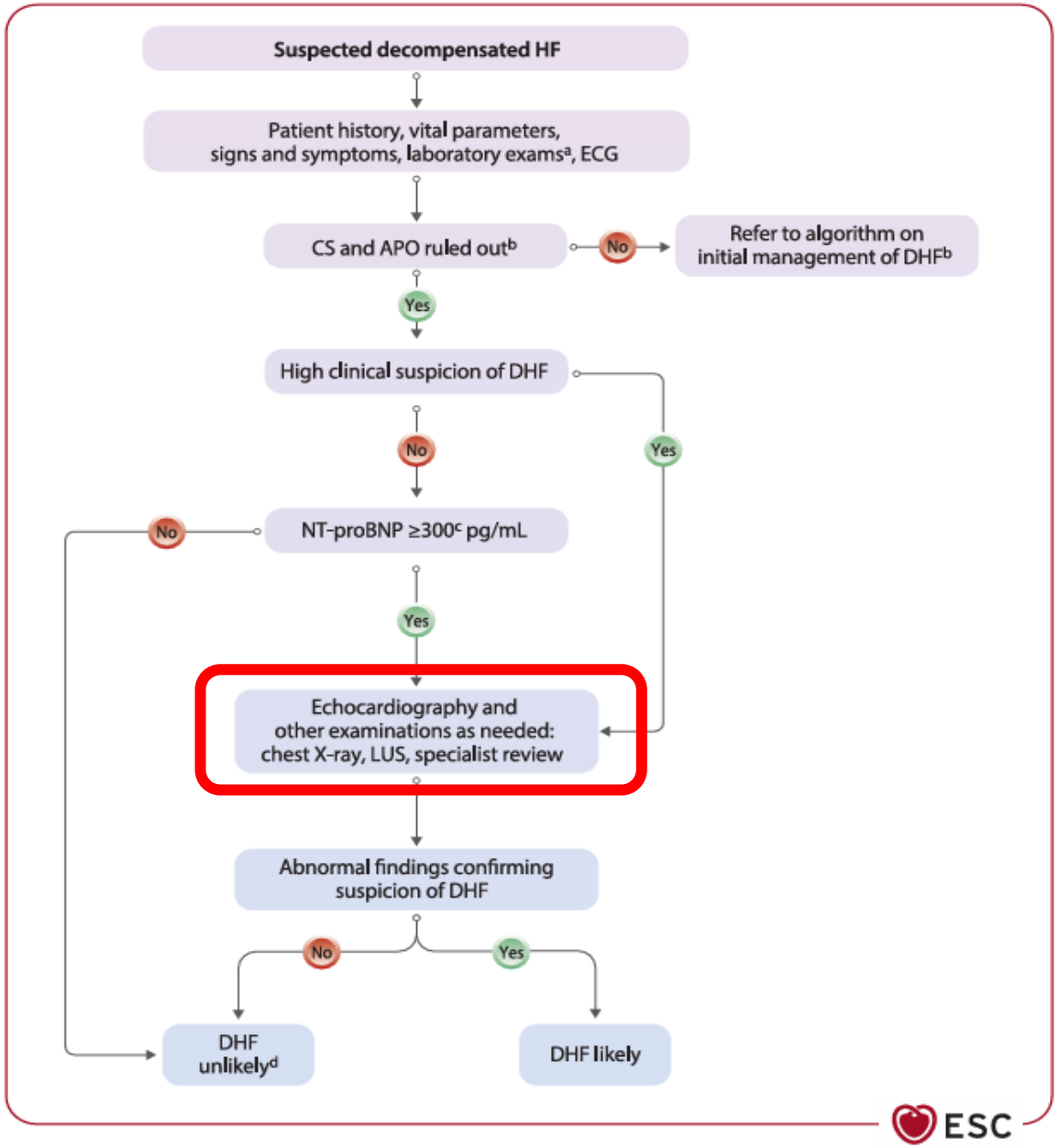

ESC Guidelines for the management of heart failure. Eur Heart J. 2026

Les lignes B peuvent-elles guider le traitement de l'insuffisance cardiaque ?

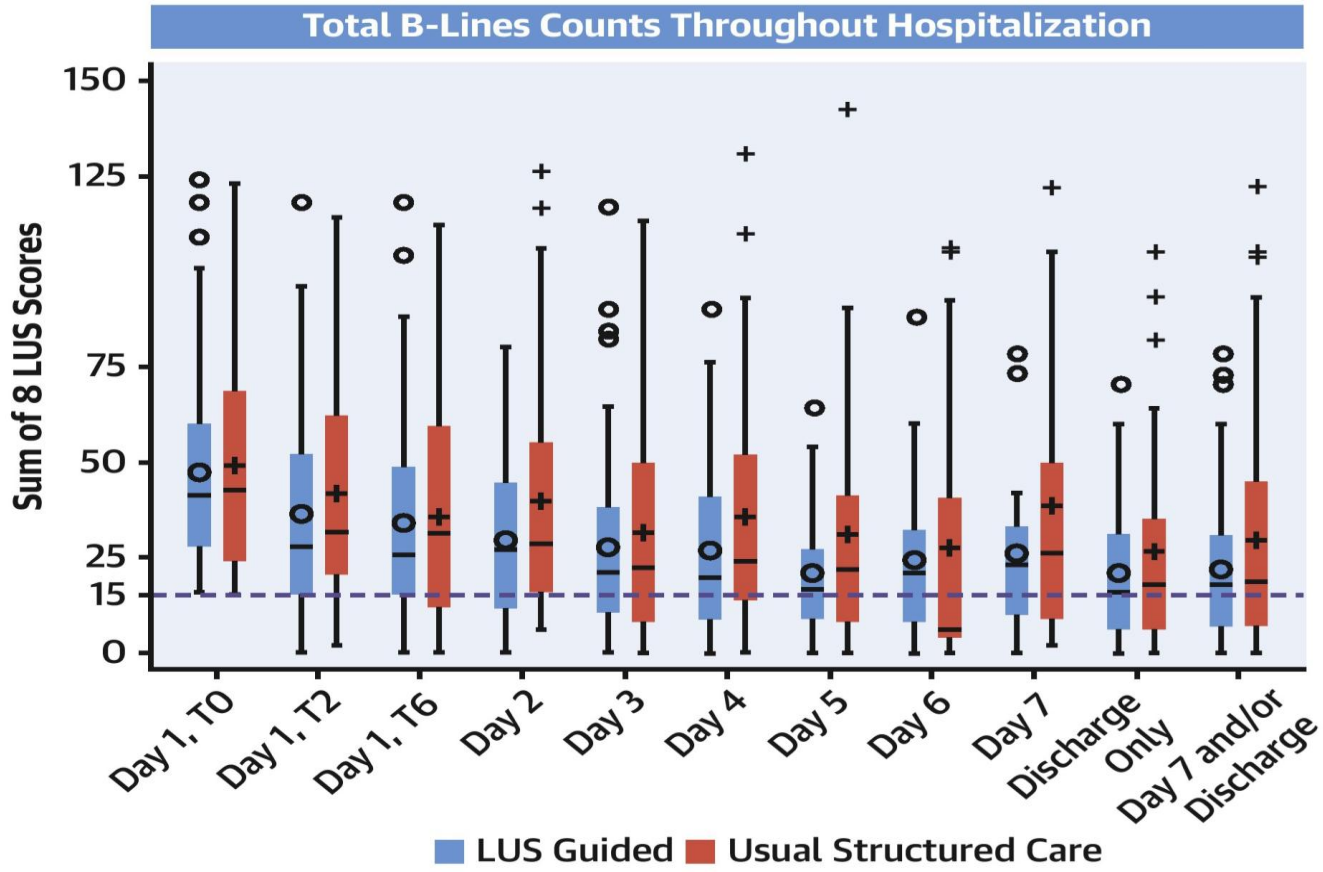

LUS-HF — Rivas-Lasarte et al., Eur J Heart Fail 2019

Lung ultrasound-guided therapy in heart failure

A randomized controlled trial

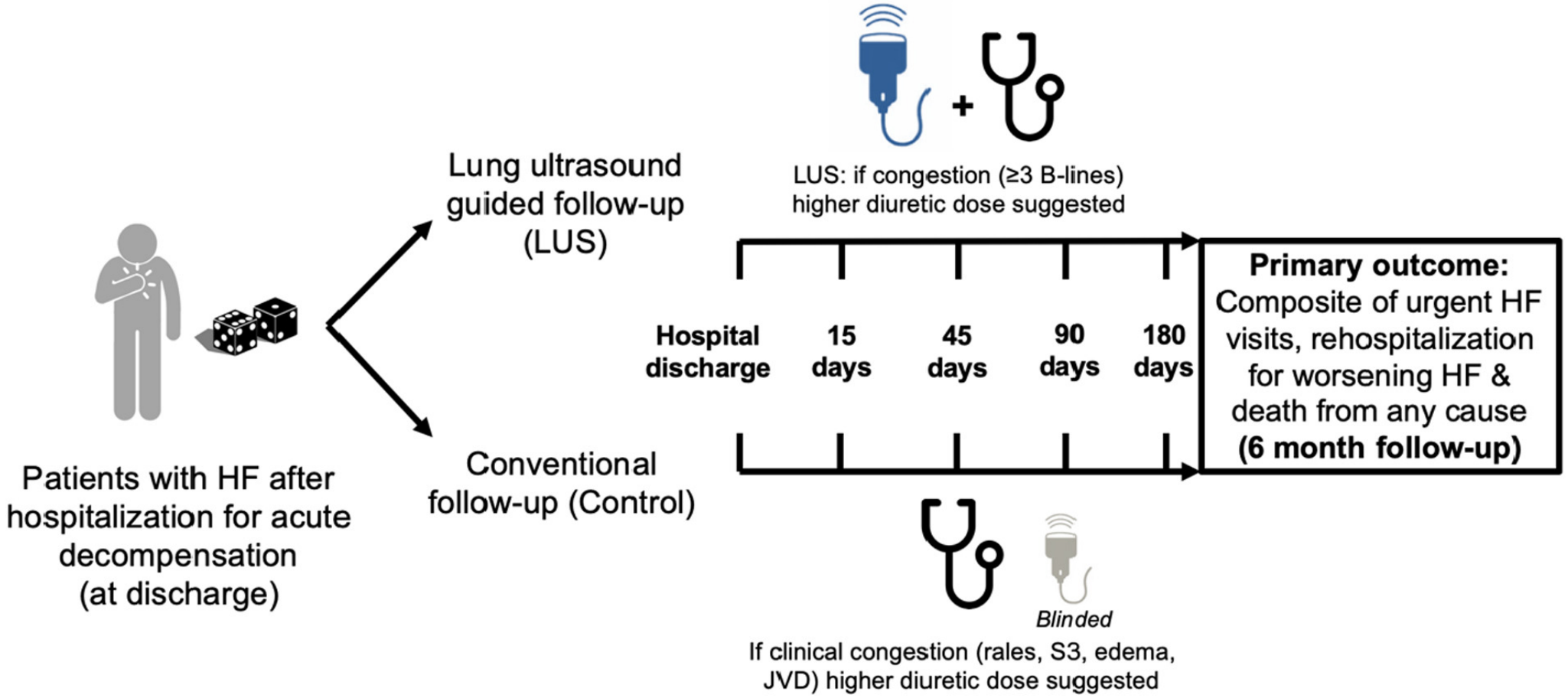

Araiza-Garaygordobil D and all. Am Heart J. 2020 Sep : PMID: 32668323.

Lung ultrasound-guided therapy in heart failure

A randomized controlled trial

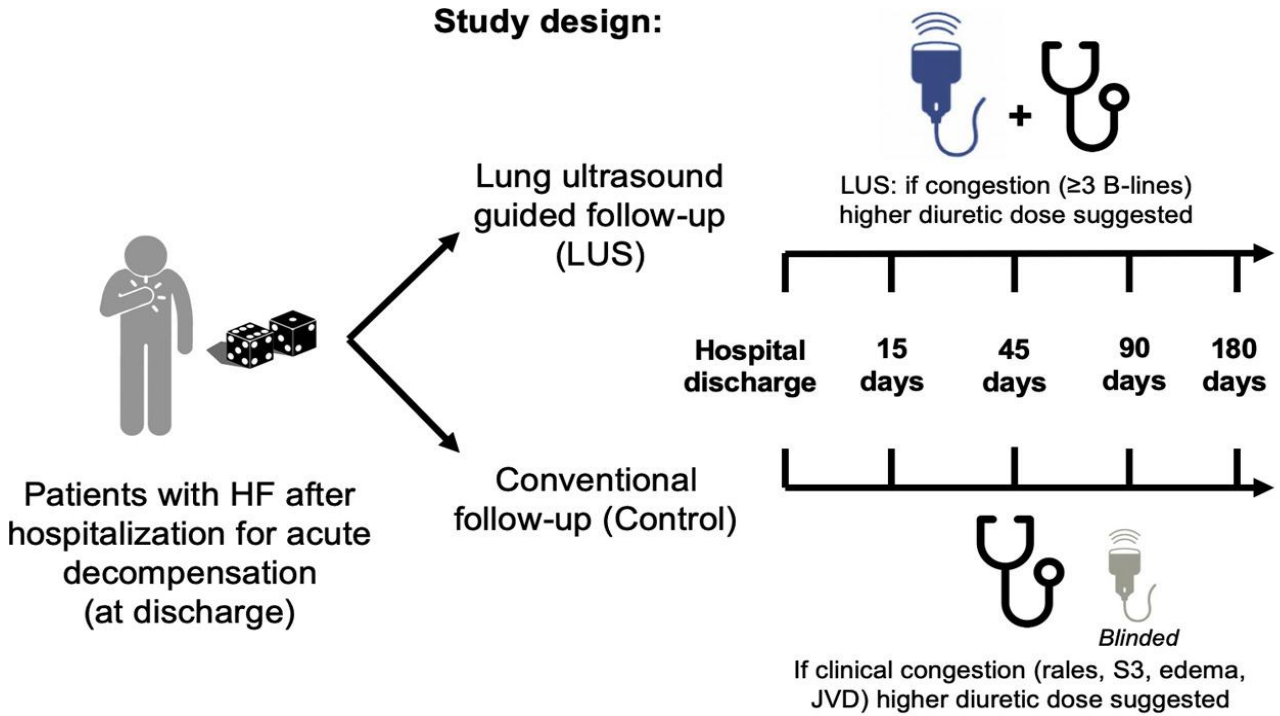

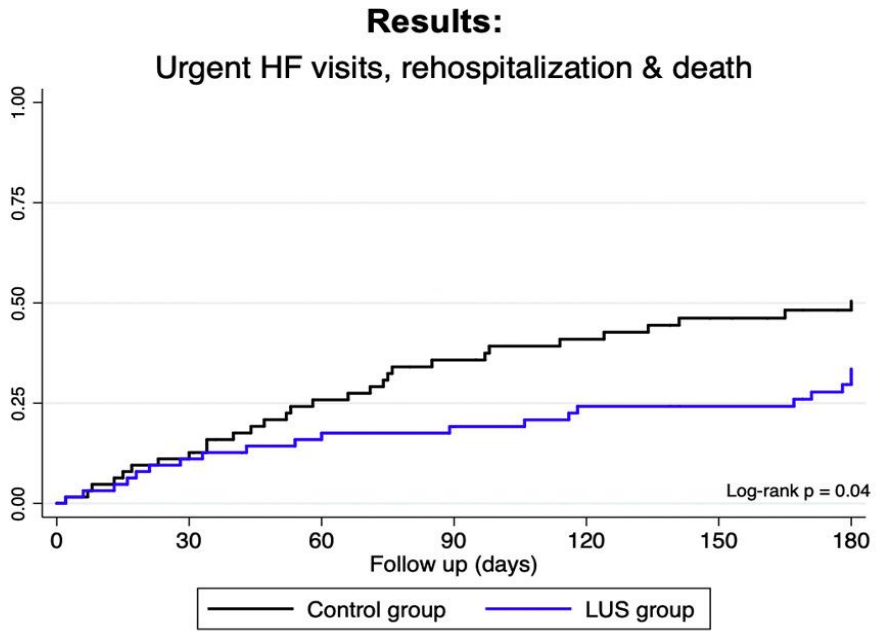

LUS guided treatment was associated with a 45% risk reduction in the primary endpoint

(HR 0.55, 95% CI 0.31 – 0.98, P = 0.044)

Araiza-Garaygordobil D and all. Am Heart J. 2020 Sep : PMID: 32668323.

ESC 2026 : l'échographie pulmonaire pour évaluer la décongestion

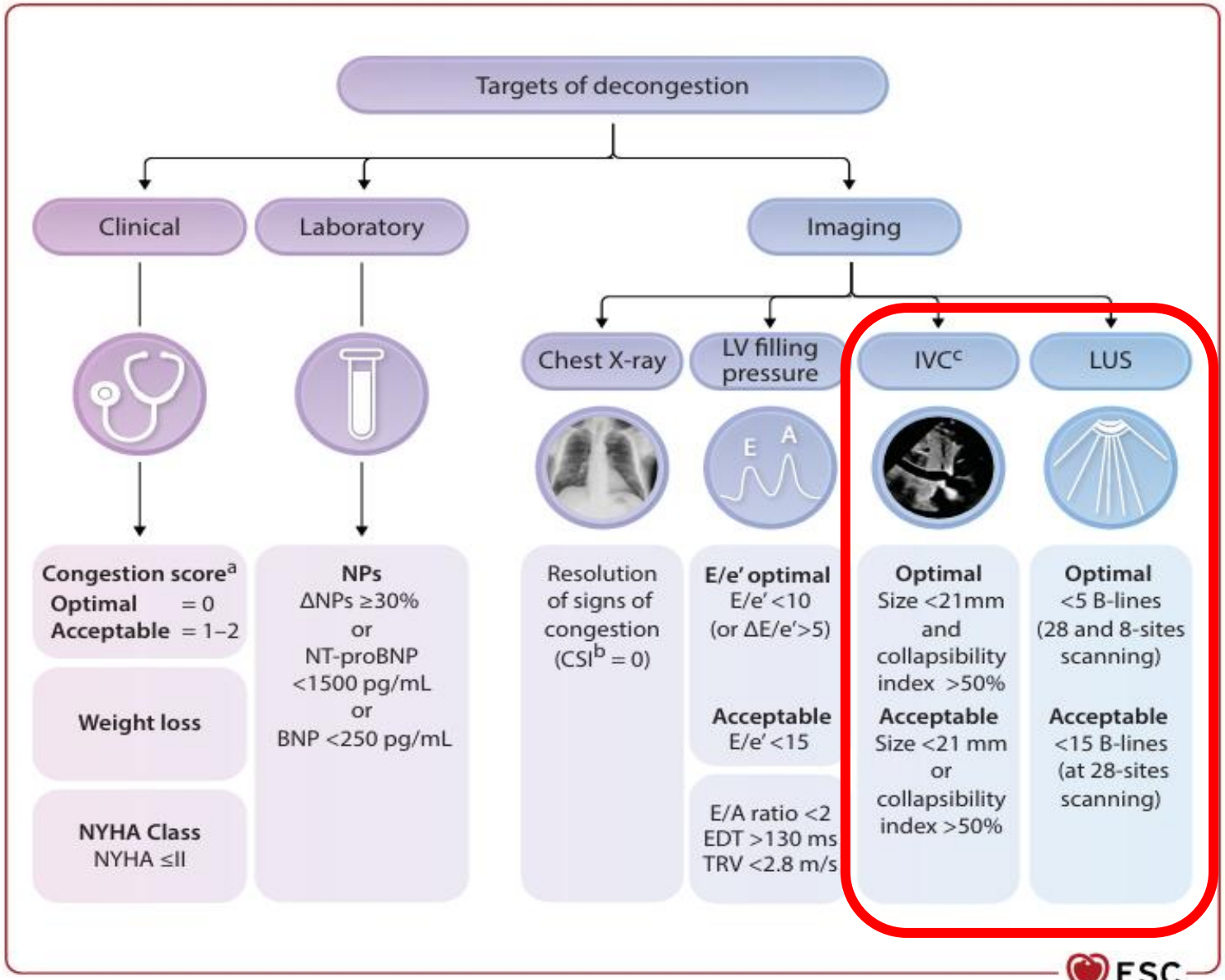

ESC Guidelines for the management of heart failure. Eur Heart J. 2026

Veine cave inferieure







Epanchement pleural

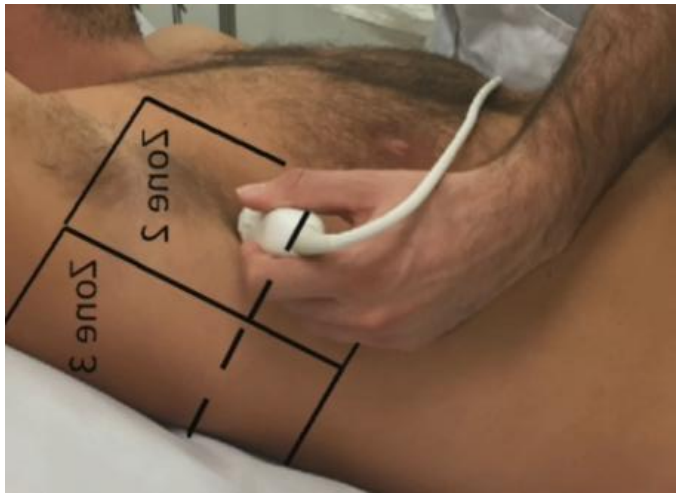

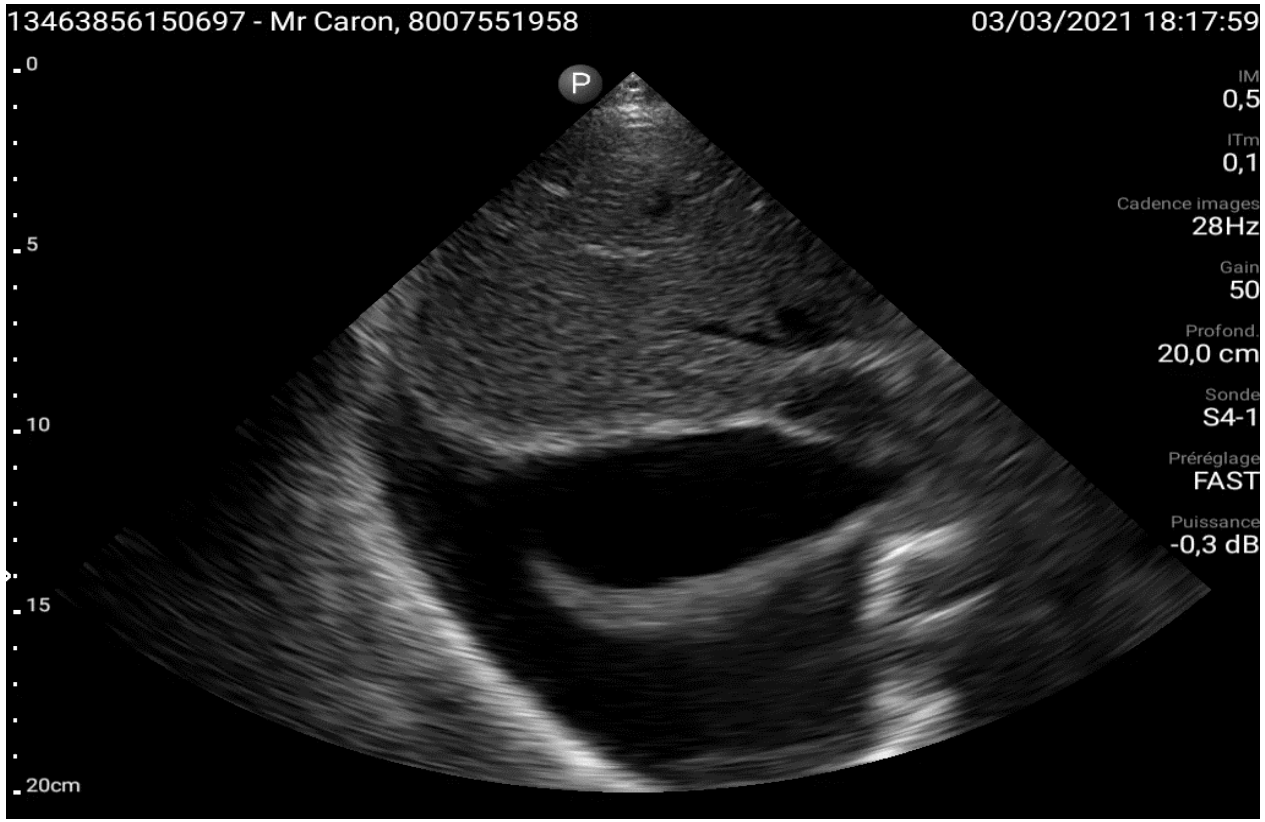

Libre, déclive, entre le diaphragme et la plèvre viscérale .

« Transonore » conduction des US et visualisations des structures profondes

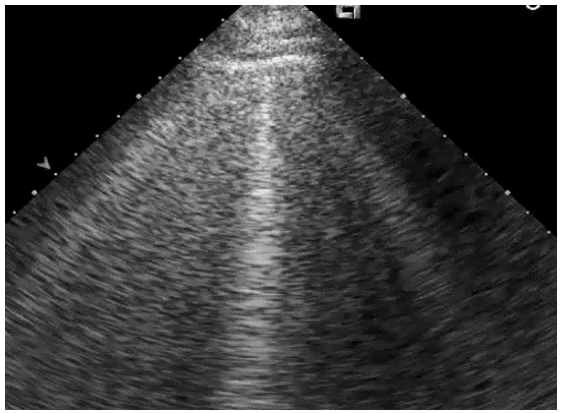



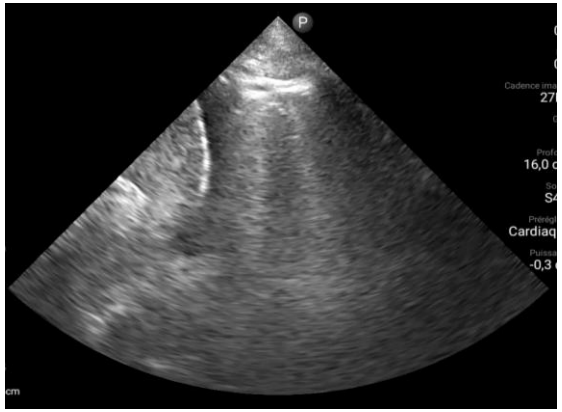
P
Cardiaq

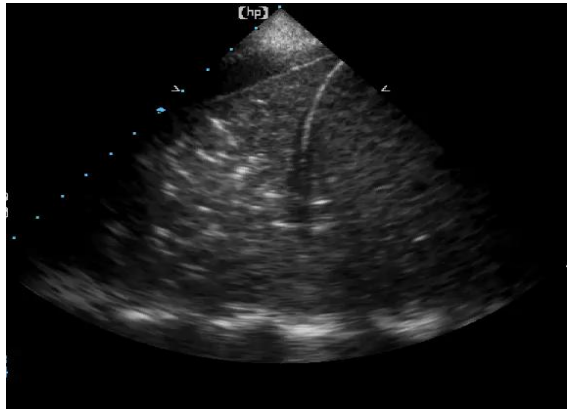
hp



Annie 91 ans Dyspnée

Quels diagnostics retenir ?

A- Insuffisance cardiaque décompensée

B- Pneumopathie

C- Epanchement pleural

D- Infection virale (Covid)



Annie 91 ans Dyspnée

Quels diagnostics retenir ?

- ✓ A- Insuffisance cardiaque décompensée
- ✓ B- Pneumopathie
- ✓ C- Epanchement pleural
- ✓ D- Infection virale (Covid)



Les gériatres non expérimentés en échographie peuvent-ils évaluer la FEVG ?

=> l'intelligence artificielle



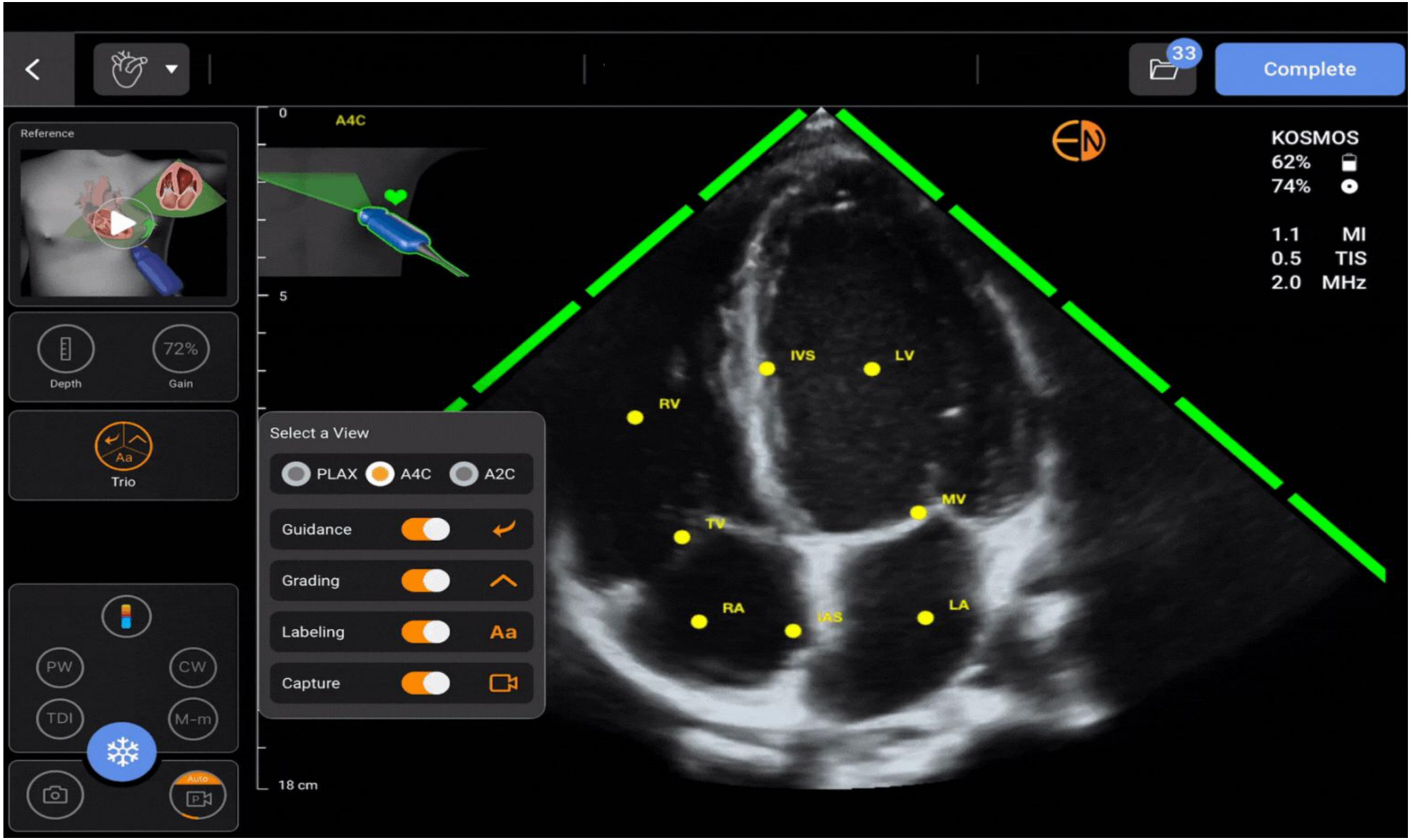
Complete
33
A4C
Reference
Depth
72%
Gain
Trio
Select a View
PLAX
A4C
A2C
Guidance
Grading
Labeling
Aa
Capture
PW
CW
TDI
M-m
Auto
KOSMOS
62%
74%
1.1 MI
0.5 TIS
2.0 MHz
IVS
LV
RV
MV
TV
RA
IAS
LA
0
5
18 cm

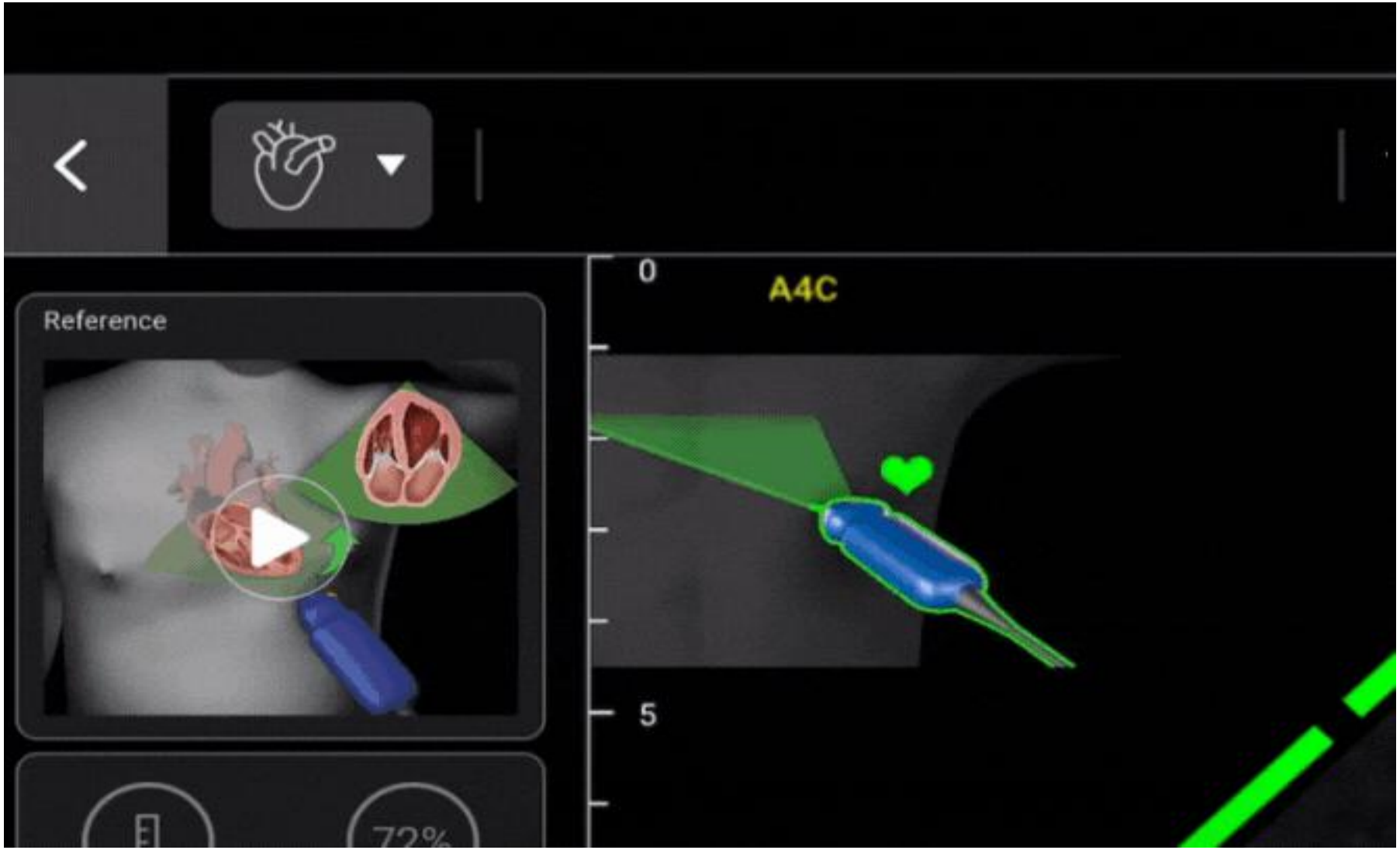
Reference
0
A4C
5
72%

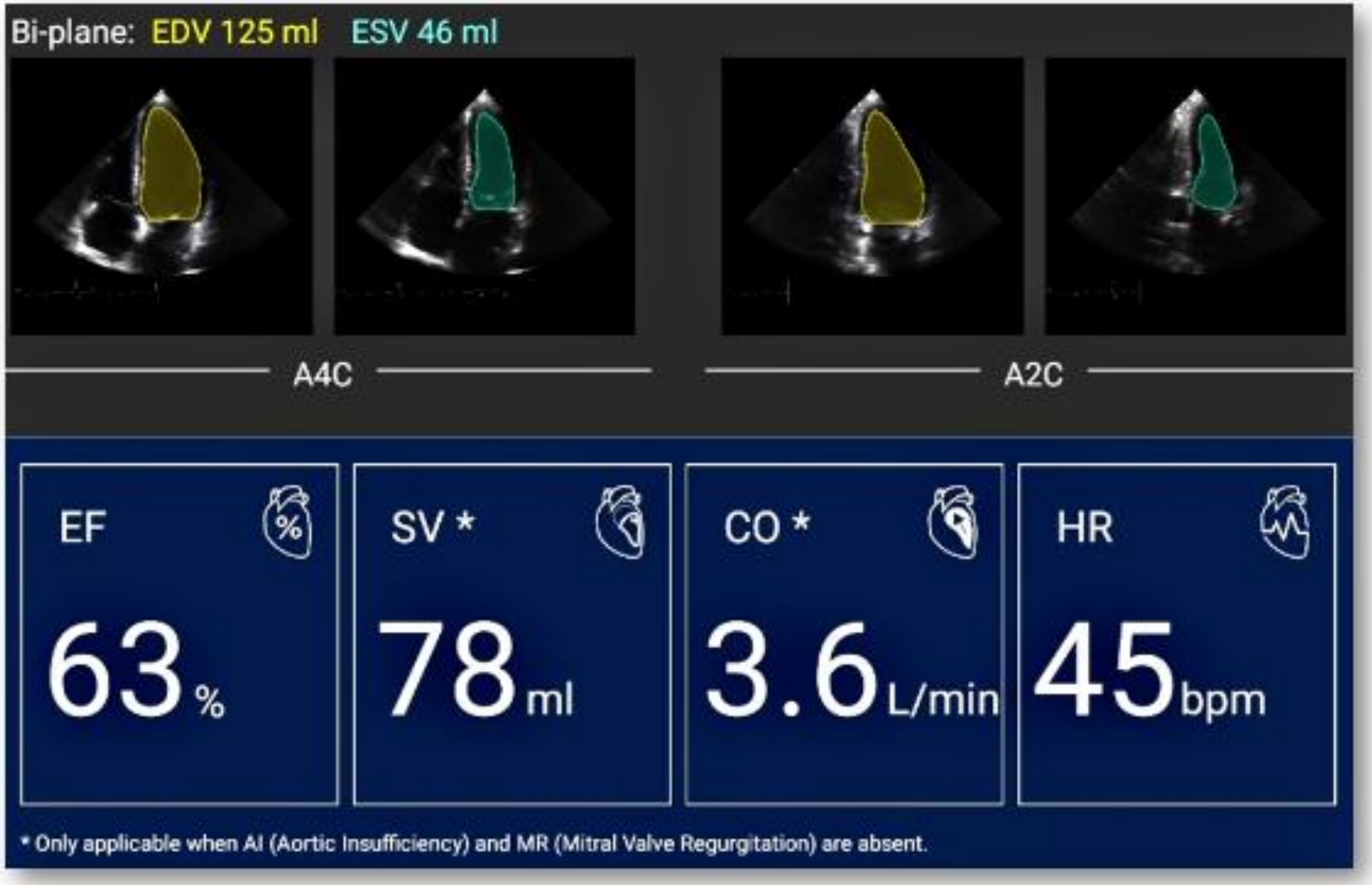
Bi-plane: EDV 125 ml ESV 46 ml
A4C
A2C
EF
63 %
SV *
78 ml
CO *
3.6 L/min
HR
45 bpm
* Only applicable when AI (Aortic Insufficiency) and MR (Mitral Valve Regurgitation) are absent.

Age moyen 90 ans
Hospitalisés pour ICA










KOSMOS



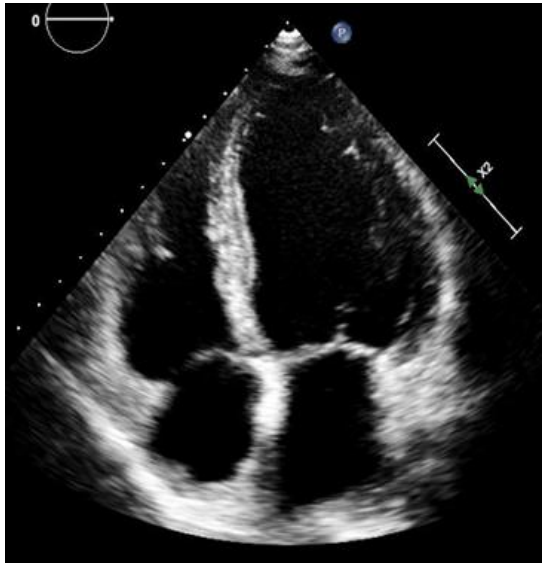
0
x2

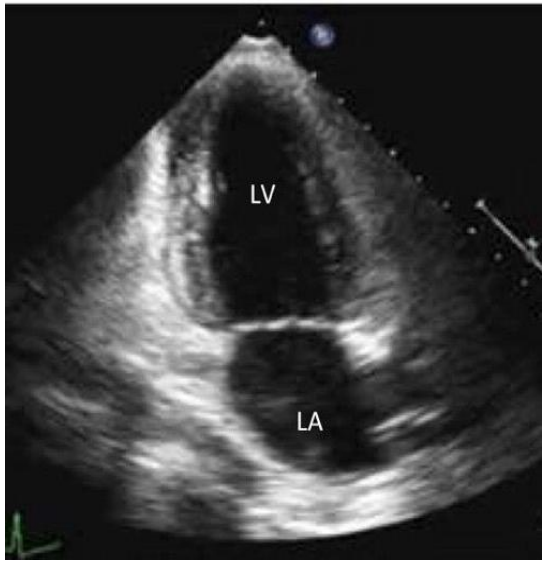
LV
LA

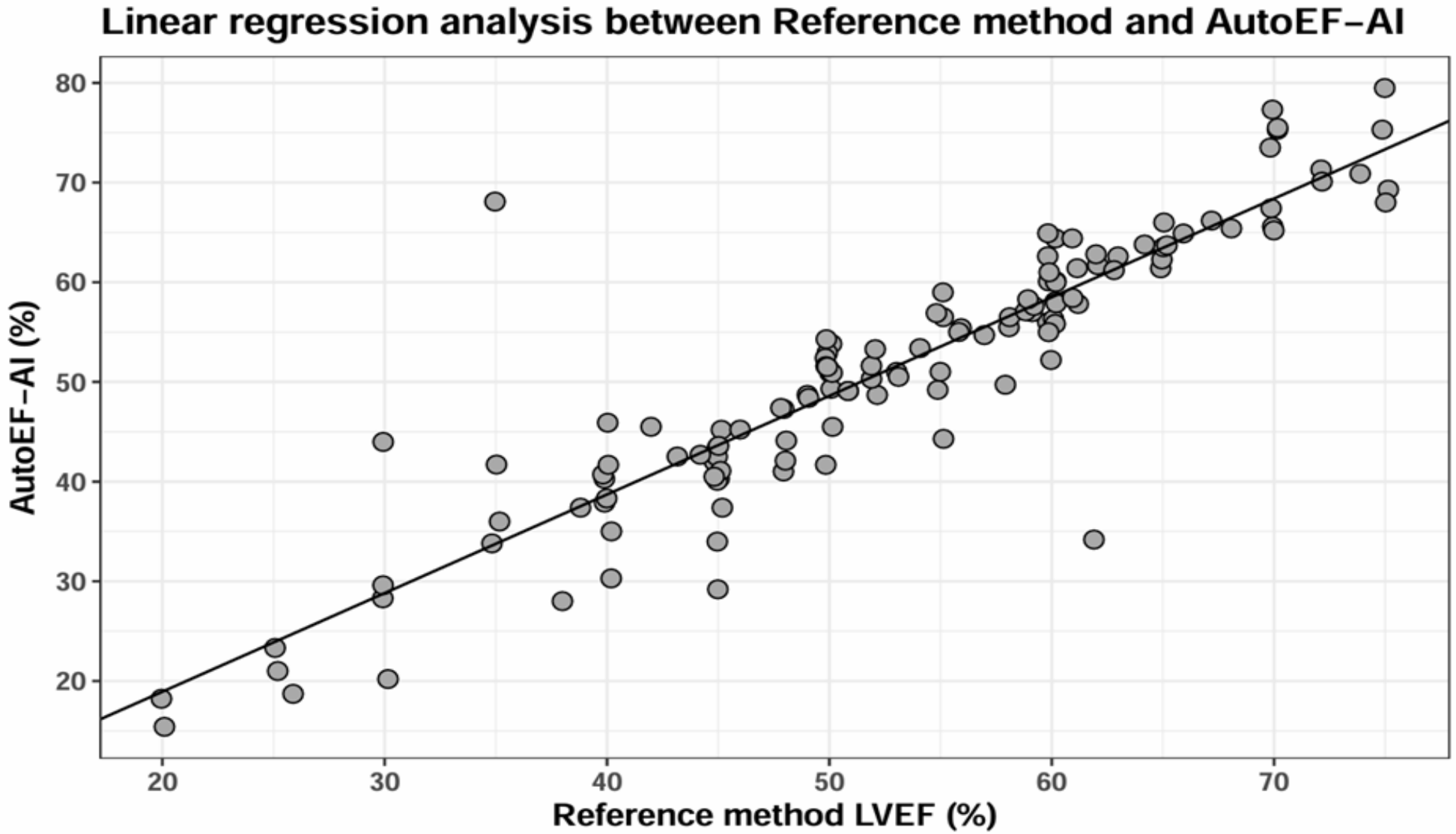

ICC = 0.90
Kappa = 0.72
Se = 97 %
Sp = 87 %

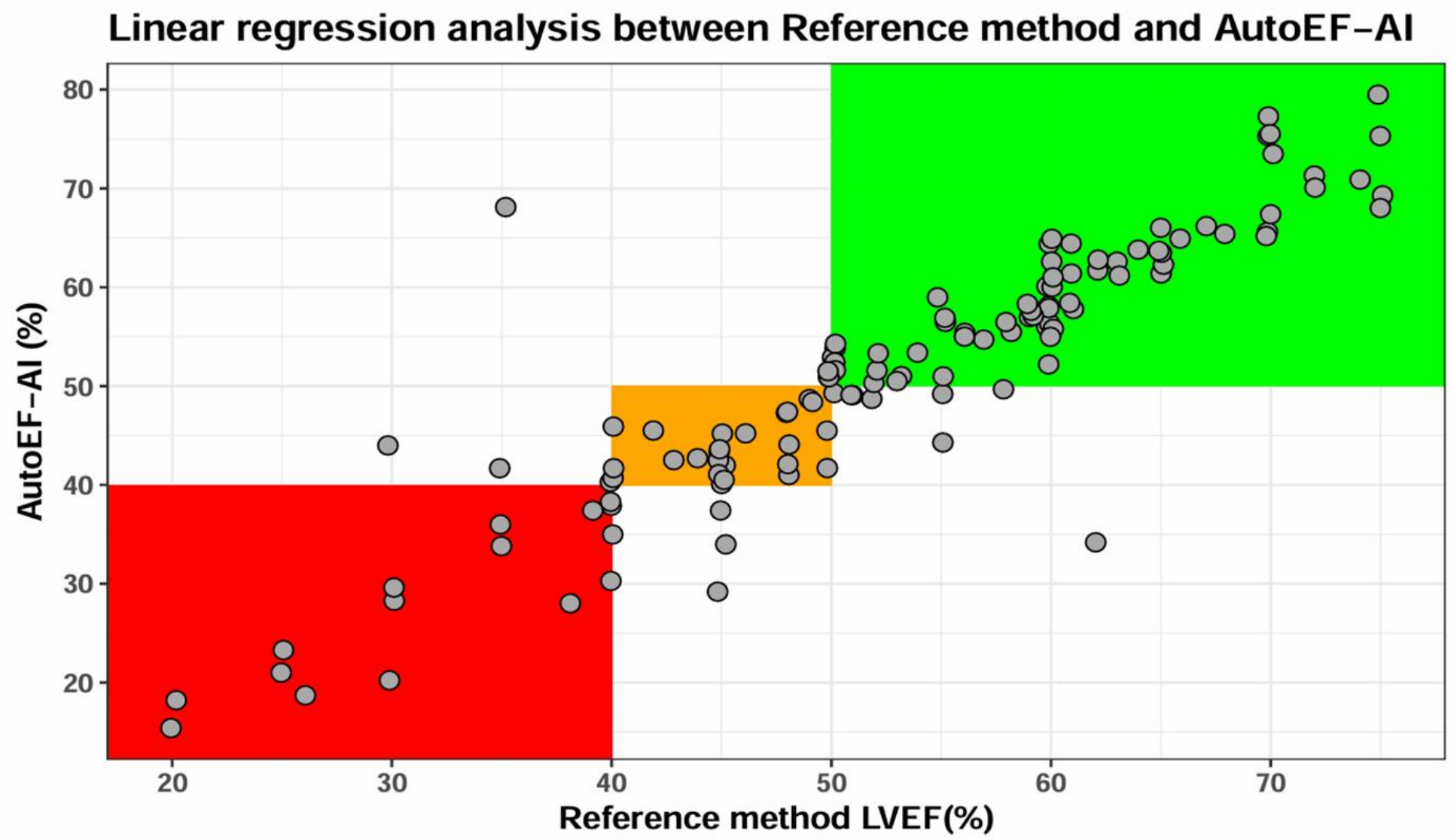
Linear regression analysis between Reference method and AutoEF–AI
AutoEF–AI (%)
Reference method LVEF(%)
80
70
60
50
40
30
20
20
30
40
50
60
70

Poids (Kg)	45	**Surf C** (m2)	1,34	**DC** (l/min)	4,84		
Taille (cm)	145	**FC** (b/min)	115	**IC** (l/min/m2)	3,62		
	Hémodyn		**Mesures**		**V Aortique**		**V Mitrale**
Flux Pul/Tric		**VG**		**STENOSE**		**STENOSE**	
VTI Pulm (cm)		**DTD** (mm)	53,0	**CC** (mm)	20,0	**Surf plani** (cm2)	
V protod (m/s)		**DTS** (mm)	43,0	**VTI CC** (cm)	13,4	**Surf PHT** (cm2)	
V téléd (m/s)		**Ep S** (mm)	9,0	**VTI Ao** (cm)		**G moy** (mmHg)	
V Tric IT (m/s)	2,47	**Ep PP** (mm)	9,0	**S Aort** (cm2)	non calc	**REGURGITATION**	
Flux Mitral		**FR** (%)	19%	**S Ao i** (cm2/m2)	non calc	**VTI m** (cm)	
E (m/s)	1,25	**MVG i** (g/m2)	130,49	**S Ao plani** (cm2)		**VTI m/VTI CC**	non calc
A (m/s)		**DTD i** (mm/m2)	39,66	**Gr max** (mmHg)		**Dia jet** (mm)	
Ea (m/s)	0,07	**h/r** (n<0,45)	0,34	**Gr moy** (mmHg)		**R PISA** (mm)	
E/Ea	17,86	**FE (Simpson)** (%)	50%	**Index perm** (%)	non calc	**Vit alia** (m/s)	
Vp (m/s)		**AORTE**		**REGURGITATION**		**V max IM** (m/s)	
E/Vp	non calc	**Aorte** (mm)		**PHT** (ms)		**VTI IM** (cm)	
Durée Am (ms)		**Sig Ao** (mm)		**Diam jet** (mm)		**Débit rég** (ml/s)	non calc
Durée Ap (ms)		**Aorte asc** (mm)		**VTD isth** (m/s)		**S orif rég** (mm2)	non calc
Ap-Am (ms)	non calc	**OREILLETTES**		**Diam V co** (mm)		**Vol rég** (ml)	non calc
PRESSIONS		**OG** (mm)		**R PISA** (mm)		**F rég** (%)	non calc
P OD (mmHg)	10,00	**Surf OG** (cm2)	31	**Vit alia** (m/s)			
PAPs (IT)	34,40	**Surf OD** (cm2)		**V max IA** (m/s)			**Val Pulm**
PAPm	non calc	**Anneau mit** (mm)		**Débit rég** (ml/s)	non calc	**Diam T AP** (mm)	
PAPd (IP)	non calc	**Anneau tric** (mm)		**S orif rég** (mm2)	non calc	**VTI ss Pul** (cm)	
Résist pulm (UW)	non calc					**QP/QS**	non calc

Y a-t-il une formation de l'échographie thoracique dédiée aux gériatres?

Y a-t-il une formation de l'échographie thoracique dédiée aux gériatres?

Les ateliers de Broca

L'échographie thoracique pour les gériatres







Y a-t-il une formation de l'échographie thoracique dédiée aux gériatres?

Les ateliers de Broca

L'échographie thoracique pour les gériatres







Y a-t-il une formation de l'échographie thoracique dédiée aux gériatres?

Les ateliers de Broca

L'échographie thoracique pour les gériatres

LinkedIn: Abdelhakim HACIL

Email: abdelhakim.hacil@aphp.fr

Journées Scientifiques de Broca

13e édition

...Merci de votre attention

LinkedIn: Abdelhakim HACIL **Email:** abdelhakim.hacil@aphp.fr

JSB 2026